

# The association between prelaminar tissue thickness and peripapillary choroidal thickness in untreated normal-tension glaucoma patients

Jae Jung, Michael Girard, Yong Kim, Ji-Hye Park, Chungkwon Yoo, Jae Hoon Jung, Michael J.A. Girard, Jean-Martial Mari, Yong Yeon Kim

► **To cite this version:**

Jae Jung, Michael Girard, Yong Kim, Ji-Hye Park, Chungkwon Yoo, et al.. The association between prelaminar tissue thickness and peripapillary choroidal thickness in untreated normal-tension glaucoma patients. *Medicine*, Lippincott, Williams & Wilkins, 2019, Vol. 98 (n°1), pp.e14044. 10.1097/MD.0000000000014044 . hal-03180274

**HAL Id: hal-03180274**

**<https://hal-upf.archives-ouvertes.fr/hal-03180274>**

Submitted on 24 Mar 2021

**HAL** is a multi-disciplinary open access archive for the deposit and dissemination of scientific research documents, whether they are published or not. The documents may come from teaching and research institutions in France or abroad, or from public or private research centers.

L'archive ouverte pluridisciplinaire **HAL**, est destinée au dépôt et à la diffusion de documents scientifiques de niveau recherche, publiés ou non, émanant des établissements d'enseignement et de recherche français ou étrangers, des laboratoires publics ou privés.

# The association between prelaminar tissue thickness and peripapillary choroidal thickness in untreated normal-tension glaucoma patients

Ji-Hye Park, MD, PhD<sup>a</sup>, Chungkwon Yoo, MD, PhD<sup>a</sup>, Jae Hoon Jung, MD<sup>a</sup>, Michael J.A. Girard, PhD<sup>b,c</sup>, Jean-Martial Mari, PhD<sup>d</sup>, Yong Yeon Kim, MD, PhD<sup>a,\*</sup>

## Abstract

To evaluate the association between prelaminar tissue thickness (PLT) and peripapillary choroidal thickness (PCT) in untreated normal-tension glaucoma (NTG) patients.

A cross-sectional study was conducted in 65 untreated NTG patients. All of the subjects were imaged with swept-source optical coherence tomography (SS-OCT, DRI OCT; Topcon, Tokyo, Japan) to obtain the horizontal scan crossing the optic nerve head center. The PLT was calculated by subtracting the anterior prelaminar depth (APLD) from the anterior lamina cribrosa depth (ALCD). The retinal nerve fiber layer thickness and PCT were measured automatically using the in-built automated software of the OCT device. Spearman correlation analysis was conducted to investigate the ocular factors that were associated with PLT.

The average PLT, APLD, ALCD, and PCT values were  $134.05 \pm 55.54$ ,  $314.59 \pm 113.59$ ,  $448.64 \pm 125.69$ , and  $121.23 \pm 59.56 \mu\text{m}$ , respectively. PLT was correlated with the axial length, visual field index (VFI), ALCD, and PCT. When the subjects were divided into 2 groups according to their PLT values (median value,  $125.114 \mu\text{m}$ ), the thin PLT group showed worse mean deviation, VFI values, and thinner PCT when compared to the thick PLT group.

The PLT was significantly associated with the PCT, and the thinner PLT showed the greater glaucomatous damage in untreated NTG. The thickness of the prelaminar tissue may be related with the choroidal blood flow in untreated NTG patients.

**Abbreviations:** AION = arteritic anterior ischemic optic neuropathy, ALCD = anterior lamina cribrosa depth, APLD = anterior prelaminar depth, BCVA = best corrected visual acuity, CI = confidence interval, ICC = intraclass correlation coefficient, IOP = intraocular pressure, LC = lamina cribrosa, MD = mean deviation, NAION = non-arteritic anterior ischemic optic neuropathy, NTG = normal-tension glaucoma, OAG = open-angle glaucoma, OCT = optical coherence tomography, ONH = optic nerve head, PCA = posterior ciliary artery, PCT = peripapillary choroidal thickness, PLT = prelaminar tissue thickness, RGC = retinal ganglion cell, RNFL = retinal nerve fiber layer, SS-OCT = swept-source OCT, VF = visual field, VFI = visual field index.

**Keywords:** choroidal thickness, lamina cribrosa, normal-tension glaucoma, prelaminar tissue, swept-source optical coherence tomography

## 1. Introduction

The optic nerve head (ONH) can be divided into 3 parts from the anterior to posterior aspect: the prelaminar region, lamina cribrosa (LC), and the retrolaminar region.<sup>[1]</sup> The prelaminar

region is also called as the anterior portion of the LC, and this region is comprised of bundles of retinal ganglion cell (RGC) axons, astrocytes, capillaries, and extracellular material. LC is characterized by fenestrated sheets of scleral connective tissue and elastic fibers. The retrolaminar region shows decrease in astrocytes and the acquisition of myelin that is supplied by oligodendrocytes. Although the principle site of RGC axonal loss in glaucoma begins at the level of the LC,<sup>[2]</sup> studies have indicated that there is also involvement of the prelaminar region in glaucomatous eyes.<sup>[3–5]</sup> Not only the mechanical stress but also the ischemic condition of the ONH has been determined to influence the thickness of the prelaminar area.

The ONH is mainly supplied by the posterior ciliary artery (PCA) circulation.<sup>[6]</sup> The prelaminar region and LC are supplied by centripetal branches from the short PCA, either directly or from the circle of Haller and Zinn, which is also formed by the short PCAs. The branches from this circle penetrate the optic nerve to supply the anterior ONH and the peripapillary choroid. Since the ONH and the peripapillary choroid share the same blood supply, reduced blood supply from the short PCA may reduce the perfusion not only to the peripapillary choroid but also to the ONH, leading the ONH vulnerable to glaucomatous damage.

The advancements in optical coherence tomography (OCT) imaging technology has allowed for the accurate visualization and measurement of the thicknesses of the ONH deep structures,

Editor: Kun Xiong.

The authors have no funding and conflicts of interest to disclose.

Supplemental Digital Content is available for this article.

<sup>a</sup> Department of Ophthalmology, Korea University College of Medicine, Seoul,

<sup>b</sup> Department of Biomedical Engineering, National University of Singapore,

<sup>c</sup> Singapore Eye Research Institute, Singapore National Eye Centre, Singapore, <sup>d</sup> University of French Polynesia, Tahiti, French Polynesia.

\* Correspondence: Yong Yeon Kim, Department of Ophthalmology, Korea University Guro Hospital, 148 Gurodong-ro, Guro-gu, Seoul 08308, Korea (e-mail: yongykim@korea.ac.kr).

Copyright © 2019 the Author(s). Published by Wolters Kluwer Health, Inc. This is an open access article distributed under the terms of the Creative Commons Attribution-Non Commercial-No Derivatives License 4.0 (CCBY-NC-ND), where it is permissible to download and share the work provided it is properly cited. The work cannot be changed in any way or used commercially without permission from the journal.

Medicine (2019) 98:1(e14044)

Received: 26 September 2018 / Received in final form: 22 November 2018 /

Accepted: 13 December 2018

<http://dx.doi.org/10.1097/MD.0000000000014044>

and of the choroid. Several studies using OCT have reported thin peripapillary choroidal thickness (PCT) and prelaminar tissue thickness (PLT) in normal-tension glaucoma (NTG) patients.<sup>[3,4,7,8]</sup> As a reduced blood supply from the short PCA may influence both of the peripapillary choroid and anterior ONH, we speculated that the incidence of a thin PCT, measured by OCT, may be interrelated with a thin PLT. In this study, we investigated the association between PLT and PCT in untreated NTG patients using swept-source OCT (SS-OCT).

## 2. Methods

We retrospectively reviewed the medical records of all consecutive patients between March 2015 to June 2016, who were aged 20 years or older, and had visited the Korea University Anam Hospital glaucoma clinic for the 1st time. We reviewed the patient medical records for their medical histories and ophthalmic examination findings, including the best corrected visual acuity (BCVA), refraction, axial length, gonioscopy, central corneal thickness, Goldmann applanation tonometry, dilated stereoscopic examination of the optic disc, color disc, and red-free fundus photography (model FF 450 Plus; Carl Zeiss Meditec AG, Jena, Germany), SS-OCT (DRI OCT; Topcon, Tokyo, Japan), and standard automated perimetry (Carl Zeiss Meditec, Dublin, CA). This study was approved by the Institutional Review Board and ethics committee of Anam Hospital, and was performed according to the tenets of the Declaration of Helsinki.

The subjects were included in this study if they met the following criteria: a glaucomatous optic neuropathy with rim thinning, notching, and a retinal nerve fiber layer (RNFL) defect; baseline intraocular pressure (IOP) of <22 mm Hg; at least 2 reliable glaucomatous visual field (VF) test results with false-positive and false-negative error rate <15%, and a fixation loss <20%; presence of a normal anterior chamber and an open angle; BCVA of >20/40; and an axial length <28 mm. Subjects were excluded if they fulfilled the following criteria: history of IOP-lowering medication use or ocular surgery; history of retinal diseases such as diabetic retinopathy, retinal vessel occlusion, or epiretinal membrane; media opacity that could affect the quality of the photograph; optic nerve disease other than glaucoma; eyes with peripapillary atrophy; or history of cerebrovascular events or systemic medication use that could affect the VF. In cases with both eyes eligible for the study, 1 eye was randomly chosen for the analysis.

### 2.1. The measurement of RNFL thickness, peripapillary choroidal thickness, and prelaminar tissue thickness

The SS-OCT operates at 1050 nm wavelength with a scanning speed of 100,000 A-scans per second. It can penetrate into the deeper layers of the eye and visualize ocular tissue, such as the choroid or even the sclera, in a short amount of time. A standard protocol for RNFL assessment using a 360° 3.4-mm diameter circle scan around the optic disc was used to investigate the RNFL thickness and PCT. The circle scan image produces 12 sectors around the disc, and each sector was numbered from 1 o'clock to 12 o'clock, as landmarks, in a clockwise direction, in the right eye, and in a counterclockwise direction in the left eye. The RNFL thickness and PCT were derived automatically from a scan using the in-built automated software for segmentation.

To measure the anterior lamellar cribrosa depth (ALCD), anterior prelaminar depth (APLD), and the PLT, the ONH was scanned with 6-mm 5-line raster scans with 0.25-mm spacing

between the scanning lines. The PLT was measured manually by using a previously reported method.<sup>[3,9]</sup> Briefly, a horizontal scan crossing the ONH center (excluding imaging of the main vessels) was selected for the measurements. The visualization of the LC and the prelaminar tissue was improved by adaptive compensation with the aid of protocols published elsewhere.<sup>[10,11]</sup> The parameters were measured from the reference line connecting the Bruch membrane opening. The ALCD and APLD were measured at the center of the reference line, and from 2 additional equidistant points, corresponding to a location 100 μm nasally and temporally away from the center of the reference line. The average value of the measurements from the 3 points was used for the analysis. The PLT was defined as the difference between the ALCD and APLD, and was obtained by subtracting the APLD from the ALCD (Fig. 1). All measurements were conducted by a single observer who was blinded to the patients' clinical data.

### 2.2. Statistical analysis


Statistical analyses were performed using SPSS software (version 21.0; SPSS, Chicago, IL). To assess the intraobserver and interobserver reproducibility, 30 randomly selected scans were evaluated by 2 independent examiners (JHP and JHJ), and the intraclass correlation coefficient (ICC) and 95% confidence intervals (CIs) were calculated. We performed a Spearman correlation analysis to investigate the factors that were associated with PLT, and post-hoc testing was conducted with an  $\alpha=0.05$  with a subsequent Holm-Bonferroni sequential correction for multiple comparison. A  $P$ -value < .05 was considered to be statistically significant.

## 3. Results

The records of 258 patients were reviewed for this cross-sectional study, and 193 of them were excluded because of the following reasons: use of IOP-lowering medication or previous history of ocular surgery (46 patients), or history of refractive surgery (13 patients), or the inadequate visualization of LC and prelaminar tissue due to the incidence of shadowing artifacts from a large vessel (20 patients). Glaucoma suspect patients (37 patients), or other glaucoma patients, including primary open-angle glaucoma (OAG), angle-closure glaucoma, and secondary glaucoma (77 patients) were also excluded. Finally, the cohort of eligible subjects comprised of 65 eyes from 65 untreated NTG patients (Table 1). The baseline IOP and mean deviation (MD) values were  $16.1 \pm 2.3$  mm Hg and  $-5.26 \pm 5.63$  dB, respectively. The average PLT, APLD, ALCD, and PCT values were  $134.05 \pm 55.54$ ,  $314.59 \pm 113.59$ ,  $448.64 \pm 125.69$ , and  $121.23 \pm 59.56$  μm, respectively. The APLD, ALCD, and PLT measurement showed excellent intra- and interobserver reproducibility (ICC > 0.850, supplementary table, <http://links.lww.com/MD/C747>).

The PLT was positively correlated with VF index (VFI), PCT, and ALCD, and negatively correlated with axial length (Table 2). However, when the multiple comparison was adjusted with Holm-Bonferroni sequential correction, the PCT ( $\rho=0.583$ ,  $P=.001$ ) and ALCD ( $\rho=0.385$ ,  $P=.02$ ) were independent factors that were significantly associated with PLT.

In the subgroup analysis, subjects were divided into 2 groups according to their median PLT value (125.114 μm): the thin and thick PLT groups. The ocular variables were compared by the Mann-Whitney  $U$  test between the 2 groups (Table 3). The PLT and PCT were significantly thicker in the thick PLT group compared to those of the thin PLT group (both  $P < .001$ ). The



**Figure 1.** Measurements of the anterior lamina cribrosa depth (ALCD) (A) and the anterior prelaminar tissue depth (APLD) (B) using swept-source optical coherence tomography (OCT). The horizontal scan crossing the center of the optic nerve head (ONH) was selected for the measurements. The reference line connecting the Bruch's membrane opening was chosen, and the ALCD and APLD were measured at the center of the reference line and at two more equidistant points, corresponding to a location at 100 μm nasally and temporally away from the center of the reference line. The average value of the measurements from the three points was used for the analysis. The prelaminar tissue thickness (PLT) was obtained by subtracting the APLD from the ALCD. Scale bar = 200 μm.

thin PLT group demonstrated significantly worse VFI and MD values compared to the thick PLT group. However, the age, IOP, and axial length were similar between the 2 groups. Figure 2 shows the representative cases of untreated NTG patients with differing severities of glaucoma and different values of PLT and PCT.

**Table 1**  
The demographics of untreated normal-tension glaucoma patients (n = 65).

	Mean ± SD	Range
Age, yr	55.71 ± 13.31	34–88
Spherical equivalent (diopters)	−1.61 ± 2.99	−9.125 to 3.00
Intraocular pressure, mm Hg	16.1 ± 2.3	12–21
Systolic blood pressure, mm Hg	129.26 ± 13.14	91–147
Diastolic blood pressure, mm Hg	79.67 ± 11.24	48–104
Pulse rate, per min	83.57 ± 12.07	59–104
Body mass index, kg/m <sup>2</sup>	23.37 ± 2.62	18.37–28.52
Axial length, mm	24.42 ± 1.43	21.65–27.48
Central corneal thickness, μm	523.26 ± 32.44	443–592
Visual field index, %	89.02 ± 16.70	17–100
Mean deviation, dB	−5.26 ± 5.63	−28.35–0.25
Pattern standard deviation, dB	4.13 ± 3.13	1.18–15.06
Average RNFL thickness, μm	87.91 ± 18.36	51–128
PCT, μm	121.23 ± 59.56	40–329
Rim area, mm <sup>2</sup>	0.82 ± 0.43	0.10–1.94
Disc area, mm <sup>2</sup>	2.29 ± 0.53	1.36–3.77
Linear cup disc ratio	0.78 ± 0.14	0.44–0.98
Vertical cup disc ratio	0.79 ± 0.13	0.36–0.99
Cup volume, mm <sup>3</sup>	0.37 ± 0.24	0.01–0.88
ALCD, μm	448.64 ± 125.69	226.401–785.104
APLD, μm	314.59 ± 113.59	103.797–569.779
PLT, μm	134.05 ± 55.54	52.186–288.131

ALCD = anterior lamina cribrosa depth, APLD = anterior prelaminar depth, PCT = peripapillary choroidal thickness, PLT = prelaminar tissue thickness, RNFL = retinal nerve fiber layer, SD = standard deviation.

#### 4. Discussion

This study investigated the relationship between PLT and PCT in untreated NTG patients. The PLT was positively correlated with PCT, and the thin PLT group showed worse MD and VFI values compared to the thick PLT group. Our results indicate that the thickness of the prelaminar region may be related with the choroidal blood flow. Moreover, PLT may differ according to the severity of the glaucomatous damage. To our knowledge, this is the 1st study that evaluated the association between PCT and PLT.

Glaucomatous optic disc cupping has 2 components to its development: prelaminar thinning and lamellar deformation.<sup>[12,13]</sup> IOP-related stress and the impairment of blood flow within the ONH can both induce changes in the prelaminar region and/or LC. Several studies have reported a relationship between IOP-related stress and lamellar and/or prelaminar

**Table 2**  
The correlation between the prelaminar tissue thickness and other ocular variables.

	Spearman rho	P-value	P-value*
Age, yr	0.015	.91	1.00
Intraocular pressure, mm Hg	0.005	.97	1.00
Axial length, mm	−0.303	.01	.15
Central corneal thickness, μm	0.014	.91	1.00
Mean deviation, dB	0.206	.10	.89
Visual field index, %	0.247	.05	.47
Average RNFL thickness, μm	0.070	.58	1.00
Rim area, mm <sup>2</sup>	0.076	.55	1.00
Vertical cup disc ratio	−0.160	.20	1.00
Cup volume, mm <sup>3</sup>	0.036	.78	1.00
PCT, μm	0.583	<.001	.001
ALCD, μm	0.385	.002	.02
APLD, μm	−0.057	.65	1.00

ALCD = anterior lamina cribrosa depth, APLD = anterior prelaminar depth, PCT = peripapillary choroidal thickness, RNFL = retinal nerve fiber layer.

\*Adjusted P-value with Holm–Bonferroni sequential correction for multiple comparisons.

**Table 3****The comparison between the 2 groups according to the thickness of the prelaminar tissue (mean  $\pm$  SD).**

	Thin group (PLT < 125 $\mu$ m, n = 32)	Thick group (PLT > 125 $\mu$ m, n = 33)	P-value*
Age, yr	57.19 $\pm$ 10.52	54.27 $\pm$ 15.59	.30
Spherical equivalent (diopters)	-1.72 $\pm$ 2.90	-1.50 $\pm$ 3.12	.36
Intraocular pressure, mm Hg	16.1 $\pm$ 2.4	16.0 $\pm$ 2.2	.99
Axial length, mm	24.69 $\pm$ 1.46	24.15 $\pm$ 1.38	.16
Central corneal thickness, $\mu$ m	521.72 $\pm$ 39.86	524.76 $\pm$ 23.66	.82
Visual field index, %	81.59 $\pm$ 25.35	93.70 $\pm$ 10.21	.01
Mean deviation, dB	-6.95 $\pm$ 6.82	-3.62 $\pm$ 3.56	.02
Pattern standard deviation, dB	4.79 $\pm$ 3.49	3.48 $\pm$ 2.62	.10
Average RNFL thickness, $\mu$ m	85.06 $\pm$ 19.69	90.67 $\pm$ 16.81	.34
PCT, $\mu$ m	96.66 $\pm$ 41.75	146.03 $\pm$ 64.17	<.001
Rim area, mm <sup>2</sup>	0.77 $\pm$ 0.44	0.87 $\pm$ 0.42	.31
Disc area, mm <sup>2</sup>	2.26 $\pm$ 0.54	2.31 $\pm$ 0.52	.41
Linear cup disc ratio	0.79 $\pm$ 0.13	0.76 $\pm$ 0.15	.55
Vertical cup disc ratio	0.82 $\pm$ 0.12	0.76 $\pm$ 0.14	.17
Cup volume, mm <sup>3</sup>	0.36 $\pm$ 0.22	0.38 $\pm$ 0.27	.98
ALCD, $\mu$ m	417.00 $\pm$ 112.19	479.32 $\pm$ 132.03	.06
APLD, $\mu$ m	327.07 $\pm$ 107.64	302.49 $\pm$ 119.47	.35
PLT, $\mu$ m	89.92 $\pm$ 22.55	176.83 $\pm$ 42.94	<.001

ALCD = anterior laminar cribrosa depth, APLD = anterior prelaminar depth, PCT = Peripapillary choroidal thickness, PLT = prelaminar tissue thickness, RNFL = retinal nerve fiber layer, SD = standard deviation.

\* Mann-Whitney *U* test.

displacement.<sup>[4,9,14,15]</sup> Agoumi et al<sup>[14]</sup> evaluated the displacement of the anterior LC and prelaminar tissue, in response to acute elevations of IOP. The prelaminar tissue displacement was positively associated with the extent of IOP elevation. They reported that the prelaminar tissue displacement may result from the reduction in the blood volume or the axoplasmic material. The chronic effects of IOP-related stress were also reported by Jung and colleagues.<sup>[4]</sup> In their study, the prelaminar tissue was thinner in patients with OAG compared to those with NTG; IOP was also a statistically significant predictive factor of PLT. Furthermore, the consequences of surgical IOP reduction in glaucoma patients were reported to induce thickening of PLT and/or anterior displacement of LC.<sup>[15,16]</sup>

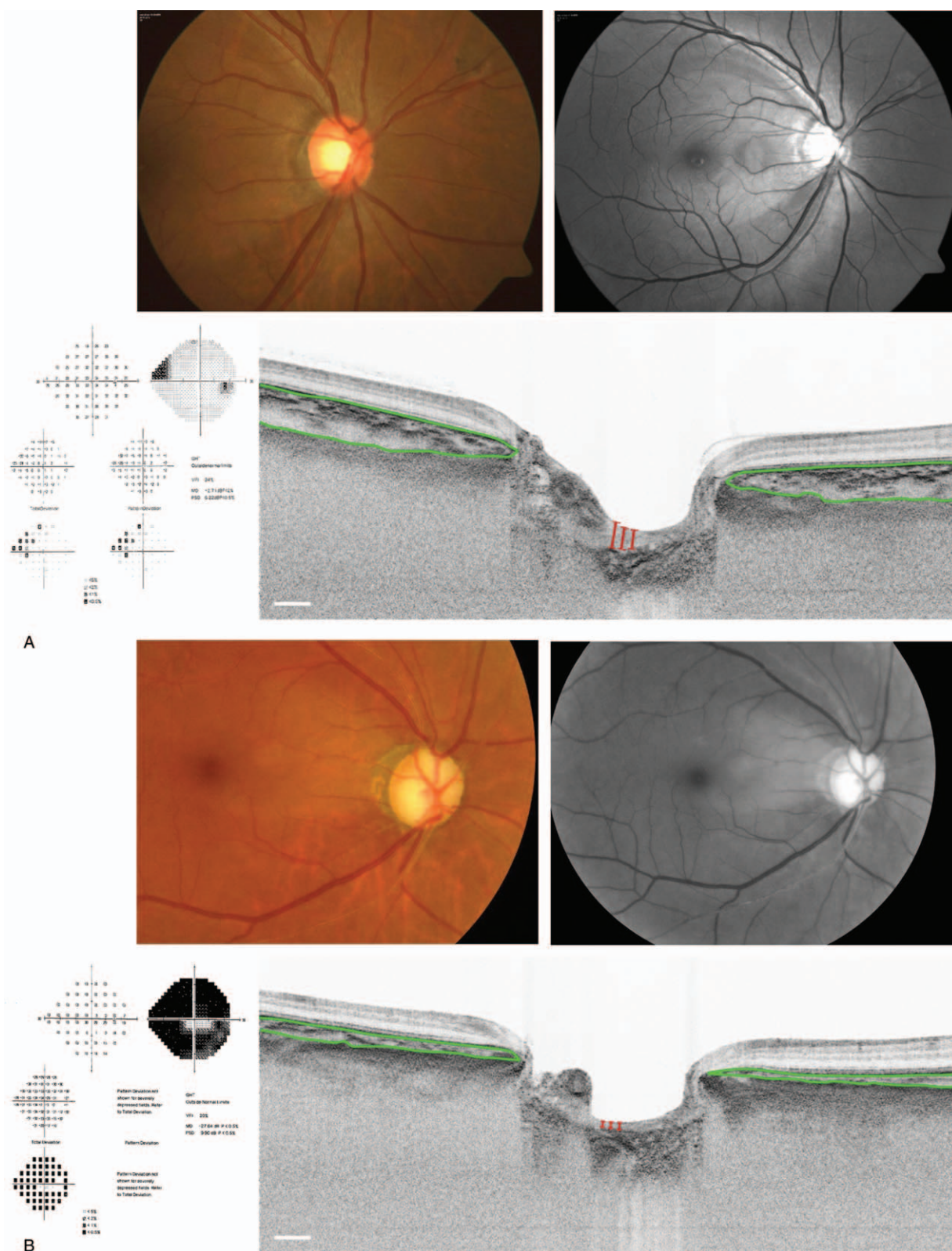
On the contrary, the impairment of blood flow to the ONH can also have an effect on the prelaminar region and LC. Hayreh<sup>[12,16]</sup> indicated that the occurrence of optic disc cupping comorbid to arteritic anterior ischemic optic neuropathy (AION) and glaucoma were due to interference with the PCA supply to the anterior part of the ONH. Danesh-Meyer et al<sup>[5]</sup> compared the optic disc topography in eyes with nonarteritic anterior ischemic optic neuropathy (NAION), AION, and OAG. They suggested that OAG affected the laminar connective tissues much more than either NAION or AION, and had resulted in an increased cup depth and volume. Moreover, AION patients with severe ischemia showed more changes in the prelaminar region compared to the less ischemic NAION patients. In summary, the ischemic changes to the ONH may have had more of an impact on the prelaminar region than on that of the LC.

The main blood supply to the ONH is from the PCA circulation.<sup>[6]</sup> Short PCAs are subdivided into 2 subgroups: paraoptic short PCA and distal short PCA. Paraoptic short PCA are few short PCAs that pierce the sclera around the entrance of the optic nerve, and supply the ONH. The majority of the short PCAs belongs to distal short PCAs, and mainly supplies the choroid up to the equator of the eye. Therefore, ONH and the posterior choroid share the same blood supply. Circulatory disturbances in the short PCAs may reduce the blood flow to the ONH and to the choroid, which may eventually result in a thin

PCT. As the ONH and peripapillary choroid are both mainly supplied by the short PCAs, we presumed that PLT and PCT would have shown a correlation. In accordance with our speculation, the present study demonstrated that PLT was positively correlated with PCT ( $\rho=0.583$ ,  $P=.001$ ).

Recent studies have reported an association between PLT and glaucoma severity or progression. Kim and colleagues<sup>[3]</sup> evaluated the difference in PLT between glaucoma patients with unilateral VF loss, and that of age-matched healthy subjects. The prelaminar tissue was significantly thinner in the VF-affected eye compared to those of the VF-unaffected eye, and in those of the healthy subjects. Additionally, Chung et al<sup>[17]</sup> investigated the value of the LC-related parameters, such as LC thickness, ALCD, and PLT, for the prediction of glaucomatous progression. They demonstrated that thinner LC and PLT were observed in the progression group. These findings suggest that the PLT would be thinner in glaucoma patients with VF damage, or in those who show glaucoma progression. Consistent with previous studies, this study also showed that a thin PLT resulted in worse MD and VFI values compared to a thick PLT, indicating that there is an association between the severity of glaucomatous damage and PLT.

This study had several limitations. First, as our study was a cross-sectional and retrospective one, we were unable to explain the temporal relationship between the incidence of choroidal thickness reduction and the thinning of prelaminar tissue, or account for the relationship between glaucomatous damage and the reduction in PLT. There are 2 possible assumptions: the reduction in blood flow supplied by the short PCAs resulted in a thin PCT. Consequently, the ischemic conditions around the ONH caused damage to the neural tissue of the prelaminar region, and eventually, resulted in the thinning of the PLT. The damaged neural tissue in the prelaminar region may have had less of a physiologic demand for a blood supply, and ultimately, cause a reduction in PCT. A longitudinal study is therefore required to further evaluate the causal relationship between PCT and PLT. Second, although there have been indirect evidences,<sup>[8,18]</sup> the choroidal thickness may not actually represent the choroid blood flow. Finally, the PLT was only measured at the horizontal scan



**Figure 2.** Representative cases showing the different severities of glaucomatous damage and the different values of the prelaminar tissue thickness (PLT) and peripapillary choroidal thickness (PCT). (A) A 42-year-old male patient had a baseline IOP of 20 mm Hg, and showed a baseline mean deviation (MD) of  $-0.83$  dB. The PLT and PCT were  $207.70$  and  $305.33$   $\mu\text{m}$ , respectively. (B) A 62-year-old female patient had a baseline IOP of 17 mm Hg and showed a baseline MD of  $-28.35$  dB. The PLT and PCT were  $88.75$  and  $72.25$   $\mu\text{m}$ , respectively. Scale bar =  $200$   $\mu\text{m}$ .

crossing the ONH center by a single observer. Future study using radial scans of the OCT may inform us about the regional variation of PCT and its potential relationship with the PLT.

Nevertheless, the present study is significant as it is the first study to evaluate the association between PCT and PLT in untreated NTG patients who had no history of medication use or surgery. Although, there have been no studies that investigated the effects of IOP-lowering medication on choroidal thickness or PLT, glaucoma filtering surgery has been reported to thicken the choroidal thickness and PLT.<sup>[9,15,19,20]</sup> Inclusion of only treatment-naive NTG patients could have excluded those confounding effect on choroidal thickness and PLT.

In conclusion, the PCT was significantly associated with the thickness of the prelaminar tissue and the thin PLT group showed worse MD and VFI values compared to the thick PLT group in untreated NTG patients. The findings of present study indicate that the thickness of prelaminar tissue may be related to the choroidal blood flow and may have an impact on the severity of glaucomatous damage.

### Author contributions

**Conceptualization:** Ji-Hye Park, Chungkwon Yoo, Yong Yeon Kim.

**Data curation:** Ji-Hye Park, Jae Hoon Jung.

**Formal analysis:** Ji-Hye Park.

**Investigation:** Ji-Hye Park.

**Methodology:** Ji-Hye Park, Chungkwon Yoo, Jae Hoon Jung, Michael J.A. Girard, Jean-Martial Mari, Yong Yeon Kim.

**Resources:** Michael J.A. Girard, Jean-Martial Mari.

**Supervision:** Chungkwon Yoo, Michael J.A. Girard, Jean-Martial Mari, Yong Yeon Kim.

**Validation:** Jae Hoon Jung.

**Writing – original draft:** Ji-Hye Park.

**Writing – review & editing:** Ji-Hye Park, Chungkwon Yoo, Jae Hoon Jung, Michael J.A. Girard, Jean-Martial Mari, Yong Yeon Kim.

Yong Yeon Kim orcid: 0000-0002-0496-4128.

### References

- [1] Allingham RR, Damji KF, Freedman S, et al. *Optic Nerve, Retina, and Choroid*. Shields Textbook of Glaucoma. 6th ed. 2011;Wolters Kluwer Health/Lippincott Williams & Wilkins, Philadelphia, PA:51–55.
- [2] Quigley HA, Addicks EM, Green WR, et al. Optic nerve damage in human glaucoma. II. The site of injury and susceptibility to damage. *Arch Ophthalmol* 1981;99:635–49.
- [3] Kim DW, Jeoung JW, Kim YW, et al. Prelamina and lamina cribrosa in glaucoma patients with unilateral visual field loss. *Invest Ophthalmol Vis Sci* 2016;57:1662–70.
- [4] Jung YH, Park HY, Jung KI, et al. Comparison of prelaminar thickness between primary open angle glaucoma and normal tension glaucoma patients. *PLoS One* 2015;10:e0120634.
- [5] Danesh-Meyer HV, Boland MV, Savino PJ, et al. Optic disc morphology in open-angle glaucoma compared with anterior ischemic optic neuropathies. *Invest Ophthalmol Vis Sci* 2010;51:2003–10.
- [6] Hayreh SS. The blood supply of the optic nerve head and the evaluation of it - myth and reality. *Prog Retin Eye Res* 2001;20:563–93.
- [7] Park HY, Lee NY, Shin HY, et al. Analysis of macular and peripapillary choroidal thickness in glaucoma patients by enhanced depth imaging optical coherence tomography. *J Glaucoma* 2014;23:225–31.
- [8] Lee KM, Lee EJ, Kim TW. Juxtapapillary choroid is thinner in normal-tension glaucoma than in healthy eyes. *Acta Ophthalmol* 2016;94:e697–708.
- [9] Barrancos C, Rebolleda G, Oblanca N, et al. Changes in lamina cribrosa and prelaminar tissue after deep sclerectomy. *Eye (Lond)* 2014;28:58–65.
- [10] Mari JM, Strouthidis NG, Park SC, et al. Enhancement of lamina cribrosa visibility in optical coherence tomography images using adaptive compensation. *Invest Ophthalmol Vis Sci* 2013;54:2238–47.
- [11] Girard MJ, Tun TA, Husain R, et al. Lamina cribrosa visibility using optical coherence tomography: comparison of devices and effects of image enhancement techniques. *Invest Ophthalmol Vis Sci* 2015;56:865–74.
- [12] Hayreh SS. Pathogenesis of cupping of the optic disc. *Br J Ophthalmol* 1974;58:863–76.
- [13] Burgoyne CF, Downs JC, Bellezza AJ, et al. The optic nerve head as a biomechanical structure: a new paradigm for understanding the role of IOP-related stress and strain in the pathophysiology of glaucomatous optic nerve head damage. *Prog Retin Eye Res* 2005;24:39–73.
- [14] Agoumi Y, Sharpe GP, Hutchison DM, et al. Lamina and prelaminar tissue displacement during intraocular pressure elevation in glaucoma patients and healthy controls. *Ophthalmology* 2011;118:52–9.
- [15] Reis AS, O'Leary N, Stanfield MJ, et al. Lamina displacement and prelaminar tissue thickness change after glaucoma surgery imaged with optical coherence tomography. *Invest Ophthalmol Vis Sci* 2012;53:5819–26.
- [16] Hayreh SS, Jonas JB. Optic disc morphology after arteritic anterior ischemic optic neuropathy. *Ophthalmology* 2001;108:1586–94.
- [17] Chung HS, Sung KR, Lee JY, et al. Lamina cribrosa-related parameters assessed by optical coherence tomography for prediction of future glaucoma progression. *Curr Eye Res* 2016;41:806–13.
- [18] Kubota T, Jonas JB, Naumann GO. Decreased choroidal thickness in eyes with secondary angle closure glaucoma. An aetiological factor for deep retinal changes in glaucoma? *Br J Ophthalmol* 1993;77:430–2.
- [19] Saeedi O, Pillar A, Jefferys J, et al. Change in choroidal thickness and axial length with change in intraocular pressure after trabeculectomy. *Br J Ophthalmol* 2014;98:976–9.
- [20] Kara N, Baz O, Altan C, et al. Changes in choroidal thickness, axial length, and ocular perfusion pressure accompanying successful glaucoma filtration surgery. *Eye (Lond)* 2013;27:940–5.